

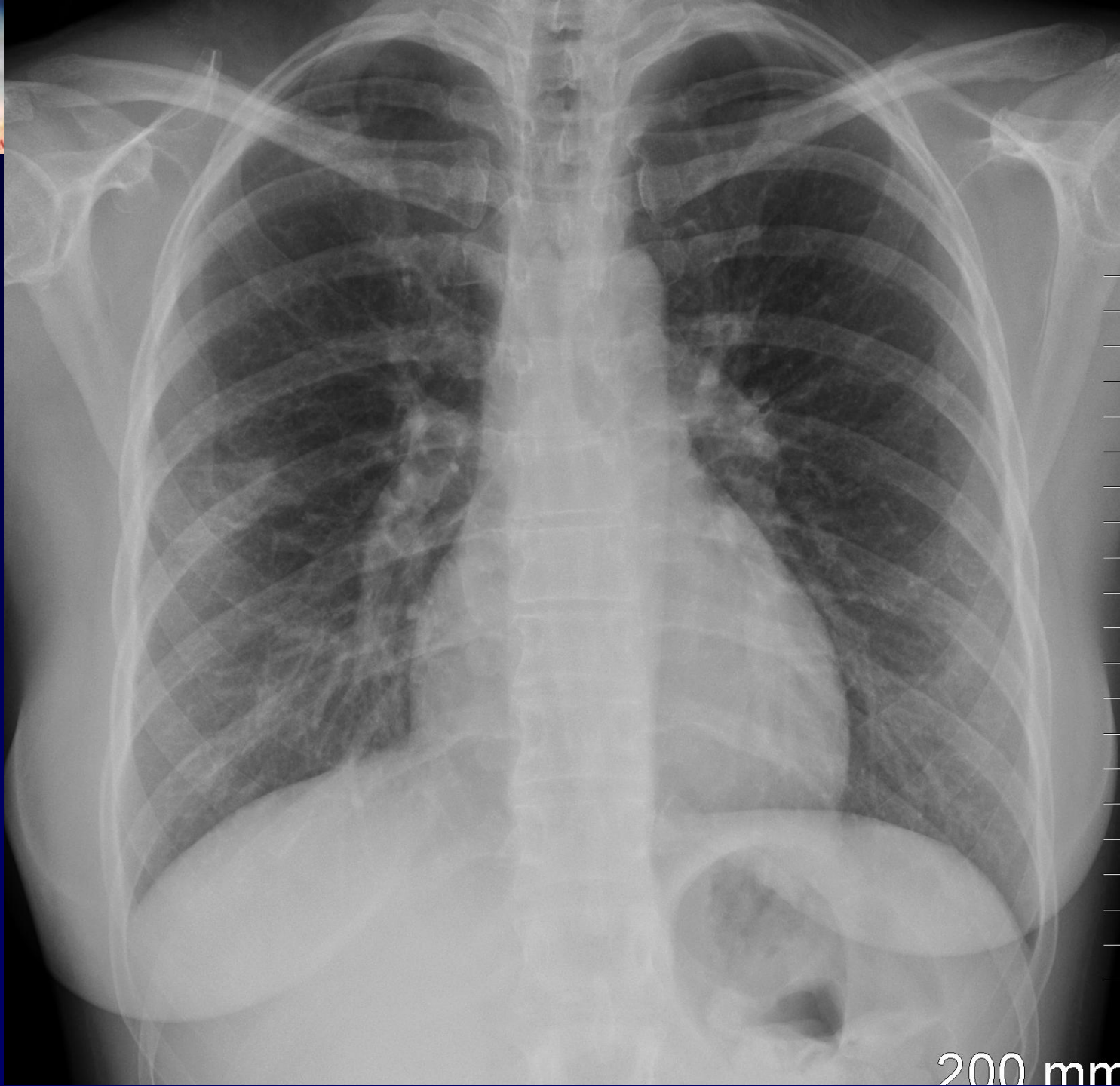
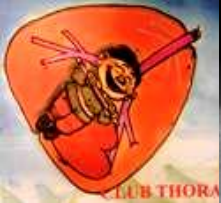

Femme de 26 ans

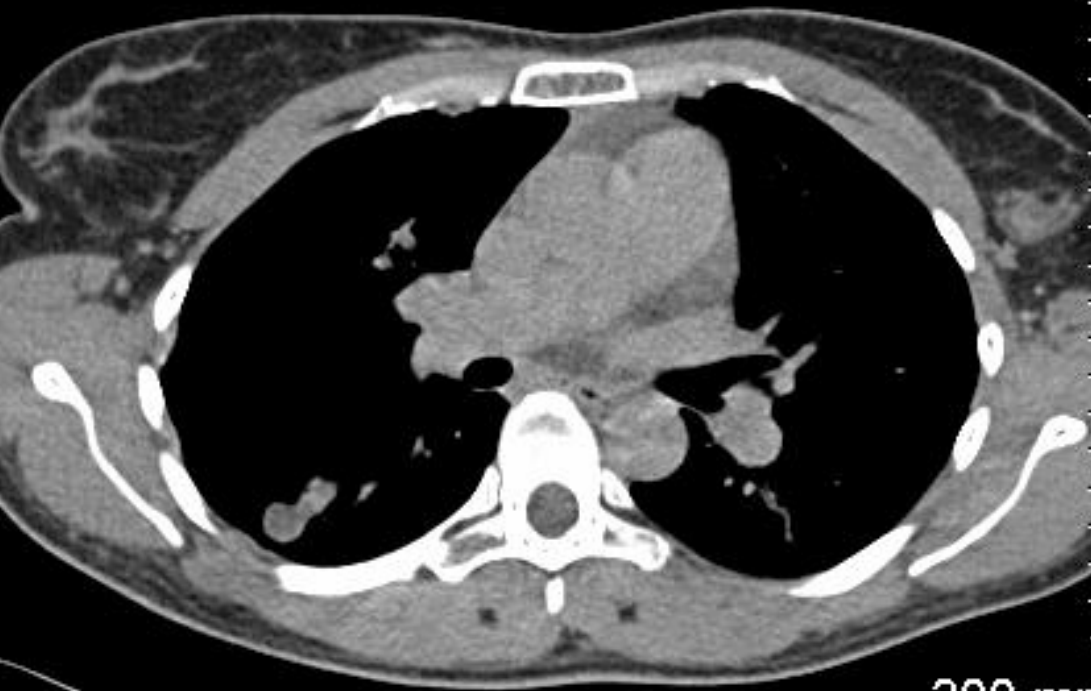RT embauche (hôpital de Lourdes)

Toux périodique signalée... banale ...

RT et TDM

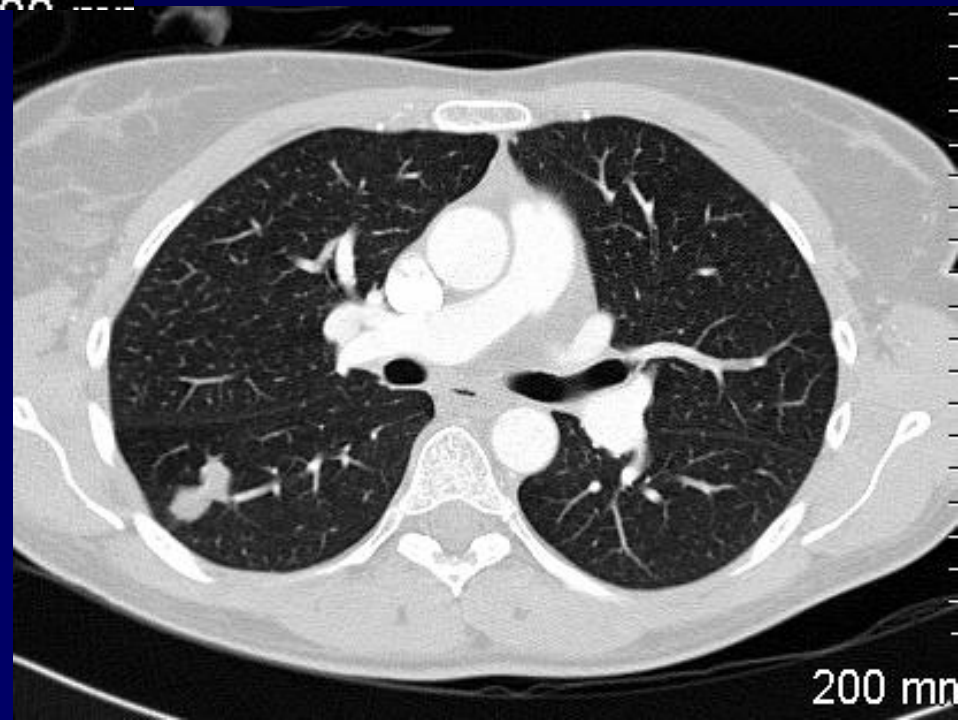


200 mm

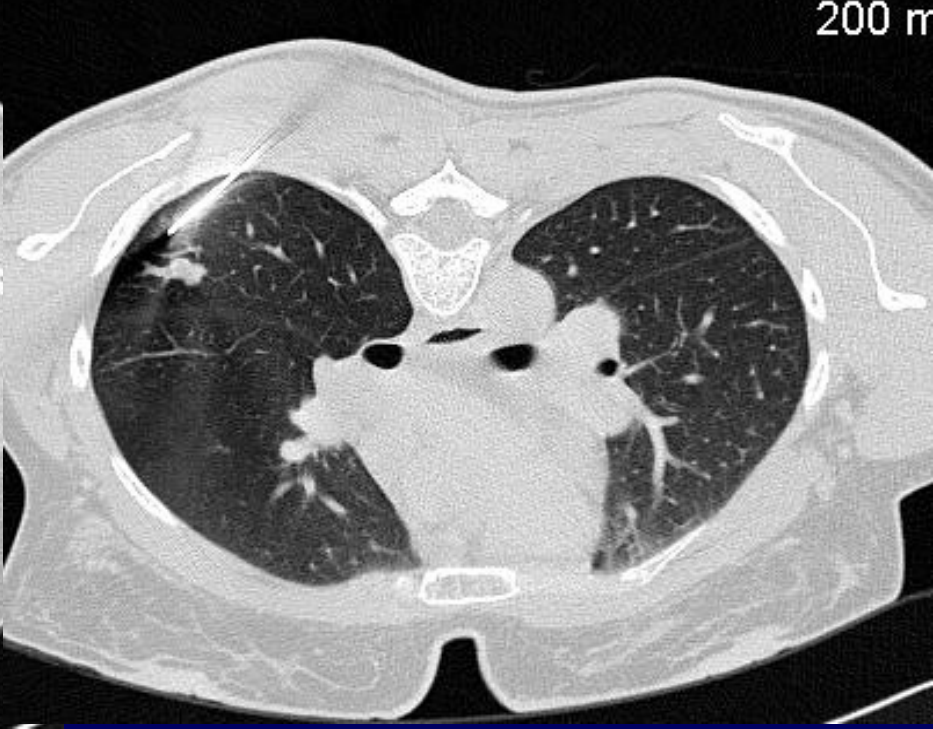
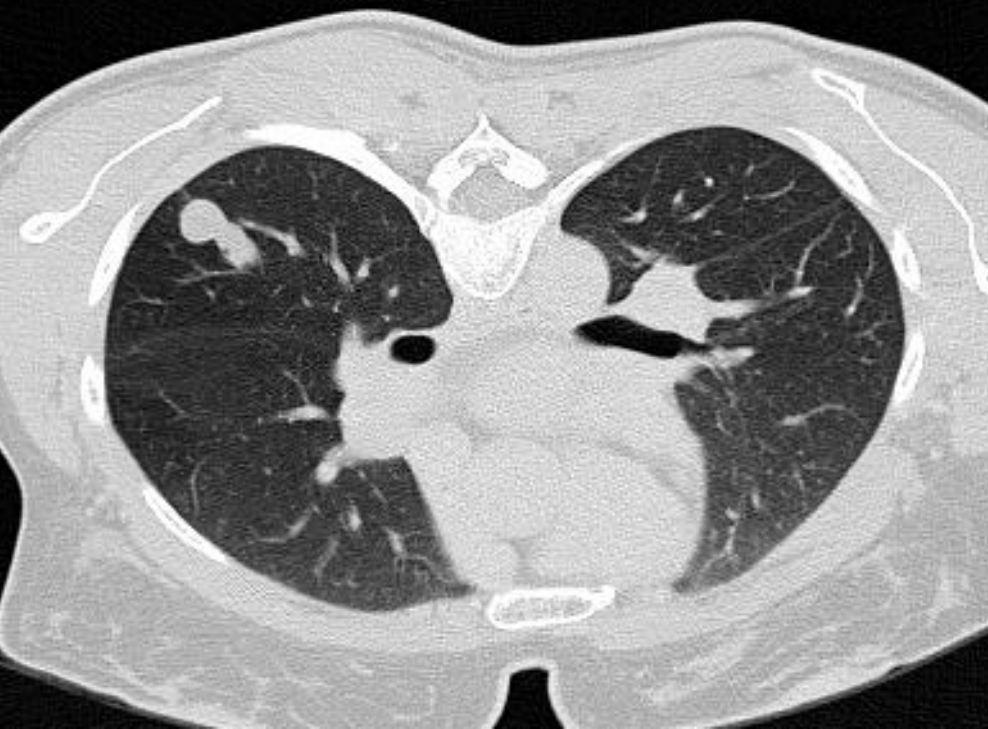


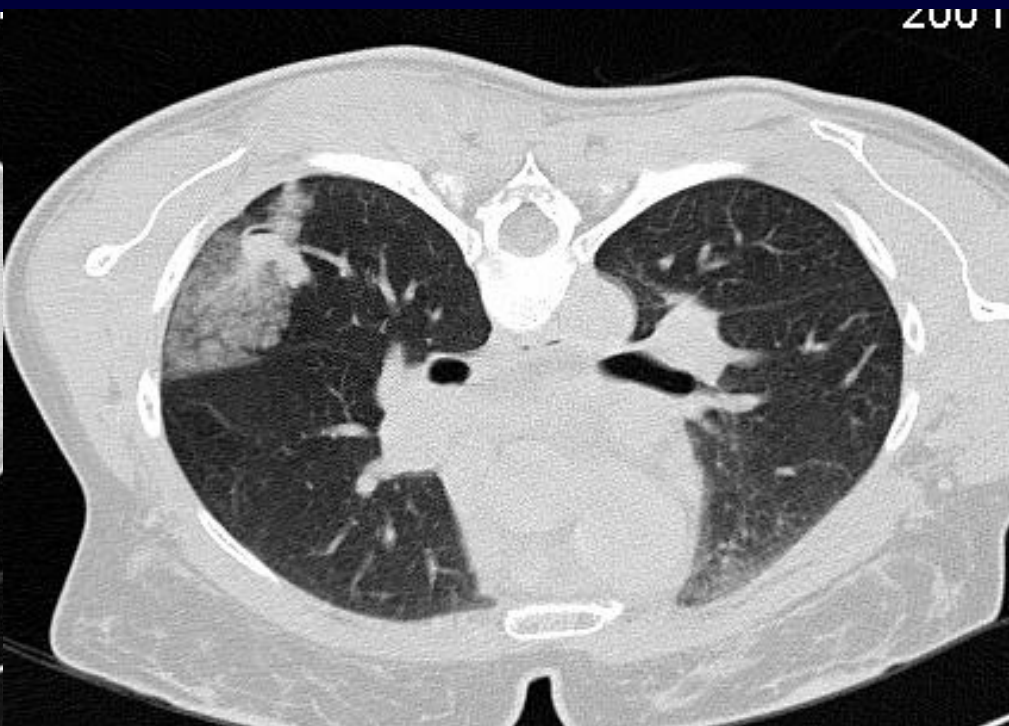
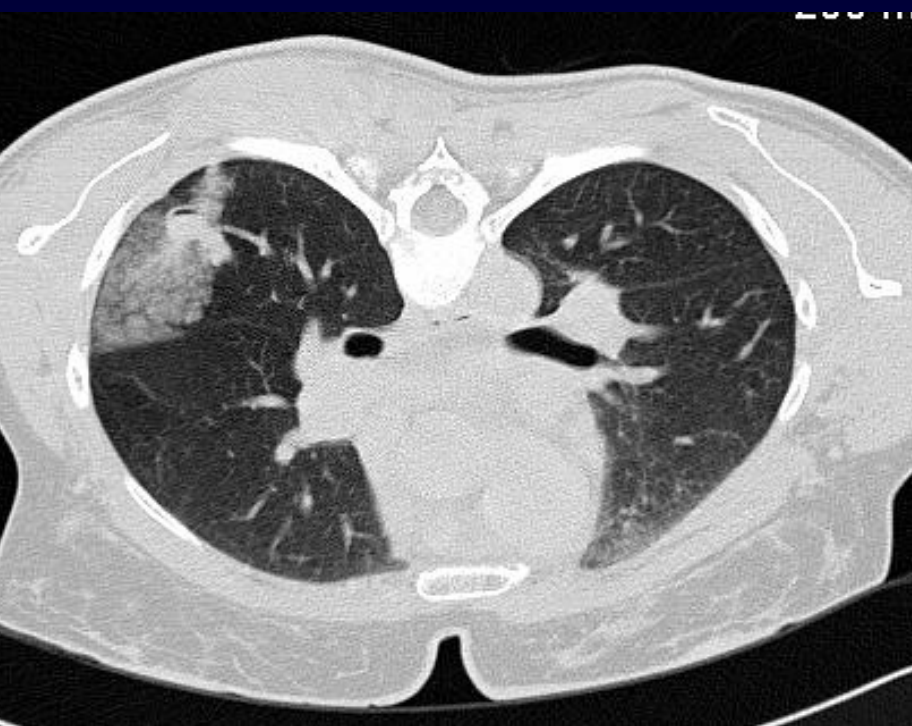
UH : 23

UH : 18



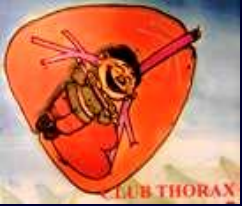200 mm







Diagnostic ?

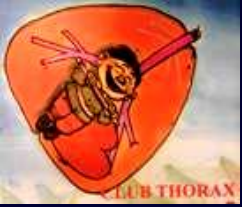

Diagnostic

BRONCHO MUCO CELE

PBT (non indispensable ?):

Pas de cellule maligne , mucus abondant



Diagnostic

Nodule :

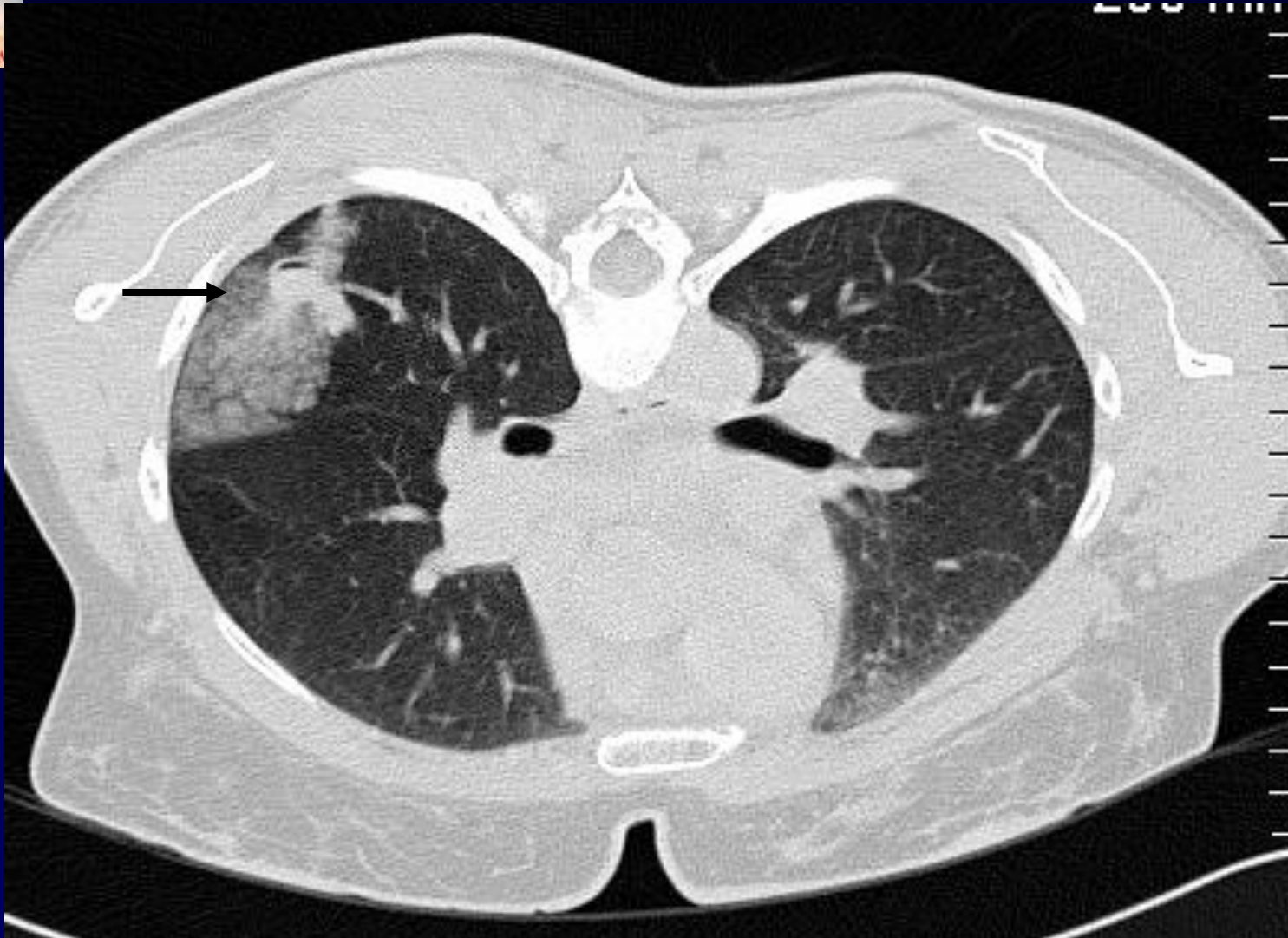
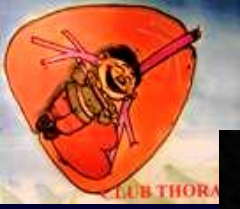Non nodulaire (« 8 de chiffre »)

Para liquide en densité

Ne prenant pas le contraste ou en périphérie

...et niveau hydro-aérique après PBT

Broncho-mucocèle



Niveau hydro –aérique post ponction